

Endocycloplasty

A new technique for managing angle-closure glaucoma secondary to plateau iris syndrome.

BY DOMINIK W. PODBIELSKI, MD; DEVESH K. VARMA, MD, FRCS; DIAMOND Y. TAM, MD; AND IQBAL IKE K. AHMED, MD, FRCS

Multiple mechanisms can contribute to angle closure, including pupillary block, plateau iris syndrome, phacomorphia, and uveal effusion syndrome. Management often includes laser peripheral iridotomy (LPI) as first-line treatment for an angle deemed to be at risk.¹ Although an LPI can relieve pupillary block, it does not address the other potential causes of angle closure. If the angle remains closed or narrow after an LPI and/or the IOP remains above target, further management may be indicated to address one of the other causes.

Plateau iris is apparent clinically as a flat iris plane, a “double-hump” appearance on gonioscopy, and often a relatively deep central anterior chamber despite the presence of a patent LPI. Anatomically, the plateau iris configuration is defined as anteriorly positioned ciliary processes that push the peripheral iris forward, resulting in iridotrabeular proximity or contact. An eye with this configuration and elevated IOP carries a diagnosis of plateau iris syndrome.²

The goal of traditional treatments is to halt the progression of glaucoma, but they do not directly address the underlying issue of anteriorly positioned ciliary processes. Ultrasound biomicroscopy studies performed before and after lensectomy demonstrate that iridociliary apposition seems to persist in plateau iris syndrome despite cataract extraction.³

Laser iridoplasty is highly effective in eliminating residual appositional closure after LPI in plateau iris syndrome. Recently, we have been studying a new technique we term *endocycloplasty* (ECPL), for which the early results are promising.

ABOUT THE PROCEDURE

Endoscopic cyclophotocoagulation (ECP) was first reported by Uram in 1992 as a technique to shrink and ablate the ciliary processes’ nonpigmented epithelium under direct visualization.⁴ Since its introduction, this procedure has proven to be useful in the treatment of various types of glaucoma and in combination with other procedures such as phacoemulsification.⁵⁻⁹ Combined with cataract surgery, ECP causes less inflamma-

tion and a lower incidence of hyphema when compared to trabeculectomy with cataract surgery.⁹ ECP has mainly been reported as a treatment in open-angle glaucoma for its effect on reducing aqueous flow. In ECPL, endoscopic diode laser energy is applied to the posterior aspect of the ciliary processes with the goal of shrinkage but not destruction. Ablation pulls the entire ciliary process, including its anterior head, posteriorly. It thereby widens the anatomic angle and flattens the peripheral iris. The procedure should also decrease aqueous production to some degree.

Because recalcitrant angle-closure glaucoma (ACG) can be difficult to manage and filtering surgery in these eyes can be challenging, phacoemulsification plus ECPL may be an effective treatment option in these eyes. There are currently no studies or publications, however, evaluating the effectiveness of ECPL.

SURGICAL TECHNIQUE

Phacoemulsification and IOL surgery are performed prior to ECPL. We prefer a clear corneal incision for ease of access and its self-sealing properties, although a limbal or scleral tunnel incision may also be used. The same incision is typically used for both phacoemulsification and ECPL. We inject a cohesive ophthalmic viscosurgical device to expand the ciliary sulcus and create space for the endoscopic probe. The 20-gauge curved ECP probe (Endo Optiks, Little Silver, NJ), which consists of a fiberoptic camera and a diode laser that emits pulsed continuous wave energy at 810 nm, is placed through the main incision. We set the laser to continuous-delivery mode with 250 to 350 mW of power. We visualize the ciliary processes by passing the curved probe behind the iris and into the sulcus. A red aiming beam is aligned with the posterior aspect of the ciliary processes. It is important to start lasering at the posterior tail aspect of the ciliary processes and to observe the processes retreat posteriorly, not anteriorly.

The endpoint of laser treatment is marked by adequate shrinkage and whitening of the ciliary process (Figure 1). The amount of energy delivered can be titrated by adjusting the distance between the probe’s tip and

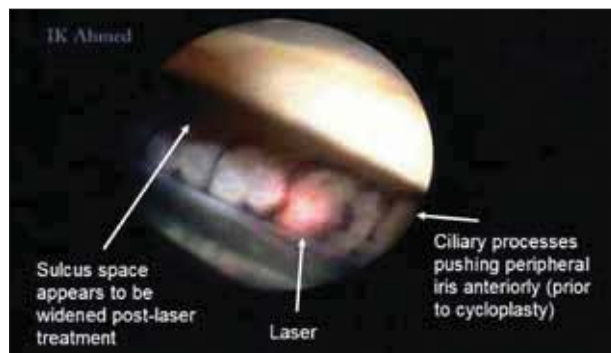


Figure 1. Treated areas show posterior shrinkage of the ciliary processes. Untreated ciliary processes are positioned anteriorly. Note that the aiming beam of the laser is positioned toward the posterior half of the process.

the ciliary process or by adjusting the power settings. Care must be taken to avoid the application of too much energy, causing the ciliary process to “pop.” Over-treatment may lead to excessive postoperative inflammation and a breakdown of the blood-aqueous barrier and its sequelae.

The curved probe is first oriented 45° to the left of the incision. We apply continuous laser energy while rotating the instrument onto new processes until the probe reaches 45° to the right of the incision. This strategy allows 270° of treatment of the ciliary body through one incision.

If we notice extensive peripheral anterior synechiae during surgery, we perform goniosynechiolysis.

After laser treatment, we evacuate the ophthalmic viscosurgical device using an automated I/A method. We then fill the anterior chamber with balanced salt solution and hydrate the wounds to ensure watertight closure.

After surgery, patients use a topical nonsteroidal anti-inflammatory drug, a topical antibiotic, and a topical steroid. Their preoperative glaucoma medications are continued at first but often may be sequentially discontinued during the postoperative period. In many cases, our patients have been able to discontinue all glaucoma medications with sufficient opening of the anterior chamber angle and a decrease in aqueous production.

PRELIMINARY RESULTS

We conducted a retrospective review of 58 patients who were treated with combined phacoemulsification and ECPL for ACG secondary to plateau iris. They were assessed postoperatively by clinical examination, anterior segment optical coherence tomography (AS-OCT), and ultrasound biomicroscopy.

Three months postoperatively, mean IOP decreased from 17.3 to 13.3 mm Hg, and the average number of

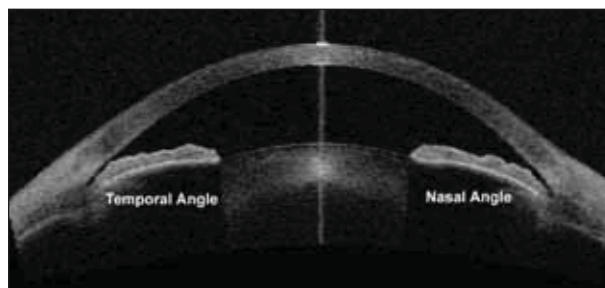


Figure 2. Preoperatively, AS-OCT of an eye with plateau iris syndrome shows that both the nasal and temporal angles are very narrow with slit/closed openings.

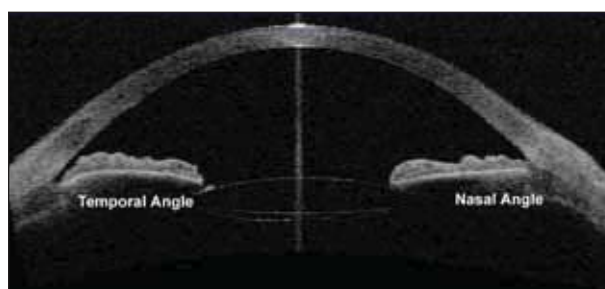


Figure 3. ECPL has mechanically opened the nasal angle. The untreated temporal angle remains very narrow with a slit opening from anteriorly positioned ciliary body processes.

glaucoma medications decreased from 1.7 to 0.7. The nasal angle, graded by Shaffer classification, widened from a mean of 0.96 to 2.82 on gonioscopy ($P < .01$ for all results).¹⁰ AS-OCT demonstrated opening of the angle postoperatively (Figures 2 and 3).

Adverse events were relatively mild, and all resolved. They included corneal edema (three patients), persistent anterior uveitis (one patient), and hyphema (two patients). Hypotony is one of the more severe complications associated with traditional ECP, but we did not observe this problem after ECPL.

CONCLUSION

Currently, no treatment definitively addresses ACG secondary to plateau iris syndrome. Phacoemulsification alone does not appear to resolve the pure plateau mechanism of angle closure due to high ciliary body insertion. Our preliminary results suggest that ECPL in combination with phacoemulsification and an IOL's implantation directly treats this underlying anatomical anomaly. The proposed technique with 270° of treatment appears to open the anterior chamber angle, lower IOP, and decrease the patient's dependence on topical glaucoma medication while maintaining a low complication profile.

The retrospective nature of our study and relatively short follow-up period have several weaknesses that will

have to be addressed with future research. Nonetheless, based on our early results, we believe that ECPL is a promising technique for the management of ACG secondary to plateau iris syndrome. A prospective randomized controlled trial comparing phacoemulsification with ECPL versus phacoemulsification alone for angle closure due to plateau iris is underway and may help to clarify the role of ECPL. At present, laser peripheral iridoplasty continues to be the standard treatment for angles that remain closed after LPI in plateau iris syndrome. □

Iqbal Ike K. Ahmed, MD, FRCSC, is an assistant professor at the University of Toronto and a clinical assistant professor at the University of Utah in Salt Lake City. He is a consultant to Endo Optiks. Dr. Ahmed may be reached at (905) 820-3937; ike.ahmed@utoronto.ca.



Devesh K. Varma, MD, FRCSC, is a staff anterior segment and glaucoma surgeon at Trillium Health Centre in Mississauga, Ontario. He acknowledged no financial interest in the products or companies mentioned herein. Dr. Varma may be reached at deveshvarma@me.com



Dominik W. Podbielski, MD, is a resident in the Department of Ophthalmology and Vision Sciences at the University of Toronto. He acknowledged no financial interest in the products or companies mentioned herein. Dr. Podbielski may be reached at dominik.podbielski@gmail.com.



Diamond Y. Tam, MD, is a clinical assistant professor in the Department of Ophthalmology at Stanford University School of Medicine in California. He acknowledged no financial interest in the products or companies mentioned herein. Dr. Tam may be reached at diamondtam@gmail.com.



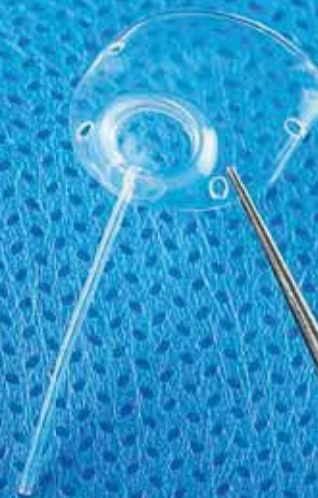1. Ritch R, Tham CC, Lam DS. Long-term success of argon laser peripheral iridoplasty in the management of plateau iris syndrome. *Ophthalmology*. 2004;111:104-108.
2. Wand M, Grant WM, Simmons RJ, et al. Plateau iris syndrome. *Trans Sect Ophthalmol Am Acad Ophthalmol Otolaryngol*. 1977;83:122-130.
3. Tran HV, Liebmann JM, Ritch R. Iridociliary apposition in plateau iris syndrome persists after cataract extraction. *Am J Ophthalmol*. 2003;135:40-43.
4. Uram M. Ophthalmic laser microendoscope ciliary process ablation in the management of neovascular glaucoma. *Ophthalmology*. 1992;99:1823-1828.
5. Gupta N, Weinreb RN. Diode laser transscleral cyclophotocoagulation. *J Glaucoma*. 1997;6:426-429.
6. Rosenberg LF, Karalekas DP, Krupin T, et al. Cyclotherapy and noncontact Nd:YAG laser cyclophotocoagulation in cats. *Invest Ophthalmol Vis Sci*. 1996;37:2029-2036.
7. Lima FE, Magacho L, Carvalho DM, et al. A prospective, comparative study between endoscopic cyclophotocoagulation and the Ahmed drainage implant in refractory glaucoma. *J Glaucoma*. 2004;13(3):233-237.
8. Berke SJ, Cohen AJ, Sturm RT, et al. Endoscopic cyclophotocoagulation and phacoemulsification in the treatment of medically controlled primary open-angle glaucoma. *J Glaucoma*. 2000;9:129.
9. Gayton JL, Van Der Karr M, Sanders V. Combined cataract and glaucoma surgery: trabeculectomy versus endoscopic laser cycloablation. *J Cataract Refract Surg*. 1999;25:1214-1219.
10. Ahmed IK, Podbielski DW, Naqi A, et al. Endoscopic cycloplasty in angle closure glaucoma secondary to plateau iris. Poster presented at: AGS Annual Meeting; March 5-8, 2009; San Diego, CA.

MOLTENO³

Third Generation
glaucoma drainage devices

Double plate performance

Single quadrant simplicity



IOP Inc.

3184-B Airway Avenue
Costa Mesa, CA 92626 USA
(714) 549-1185

(800) 535-3545

www.iopinc.com